



Unusual Complication of Incarcerated Uterovaginal Prolapse: A Case Report

Gowri Dorairajan^{1*}, N. Hima Bindu¹ and Priyadharshini Perumal¹

¹Department of Obstetrics and Gynecology Institution, Indira Gandhi Govt Medical College & Research Institute, Kadirammam, Puducherry-605009, India.

Authors' contributions

This work was carried out in collaboration between all authors. Author GD analyzed and interpreted the patient data, conceived the study and wrote the first draft of the manuscript. Authors NHB and PP collected all the information needed to write the manuscript. Authors NHB and PP managed literature searches. Author PP followed up the case. Author NHB edited the manuscript. All the authors read and approved the final manuscript.

Case Study

Received 21st June 2013
Accepted 15th August 2013
Published 14th September 2013

ABSTRACT

Aims: The case report aims to bring out a rare and life threatening complication of incarcerated utero-vaginal prolapse.

Case Report: We present a case of 55 yr old woman with incarcerated prolapse. Details of evolving clinical features and investigations that led to the suspicion of pelvic abscess are presented and discussed. Emergency intervention by colpotomy for draining the abscess was performed. Definitive surgery was performed 1 month after she fully recovered and the tissue edema and congestion subsided. Two stage management of the case is detailed.

Conclusion: Spontaneous pelvic abscess is a rare but life threatening complication of incarcerated prolapse. A two stage surgery in such a situation is associated with good outcome.

Keywords: Pelvic abscess; incarcerated prolapsed; urinary tract infection; pelvic inflammatory disease; colpotomy; proidentia.

*Corresponding author: Email: gowridorai@hotmail.com;

1. INTRODUCTION

Utero-vaginal prolapse is a common problem and prolapse surgery is the commonest surgery performed by a gynecologist. However when irreducible and incarcerated it may be associated with complications. Causal association with bilateral hydronephrosis has been reported [1]. Association with inversion [2] and invasive carcinoma [3,4] with grade IV prolapse has been reported in the literature. Irreducible prolapse invariably causes urinary retention and infection. Spontaneous pelvic abscess as occurred in the present case is a poorly reported complication of incarcerated prolapse. It has been reported earlier once when it was incidentally observed at the time of definitive surgery [5]. The case reports details the evolving clinical features that led to the diagnosis of pelvic abscess. The two staged management of the case is further detailed.

2. PRESENTATION OF CASE

A 55 year old women presented with complains of utero-vaginal prolapse for 2 years. It had increased in size and become irreducible in the last two months. She had associated urinary symptoms of increased frequency and dysuria. There was no history of stress incontinence. She had irregular menstrual cycles occurring once in three to four months with normal flow. Her last menstrual period was ten days before reporting to the hospital. She has had three spontaneous terms vaginal deliveries without any complications and thereafter had undergone tubectomy operation. There was no history of previous intra uterine device use, intrauterine procedures or surgical termination of pregnancy. She was not a known diabetic. There was no family history of malignancy. There was no history of chronic bowel disease, steroid therapy or tuberculosis.

On examination she was normotensive, mildly anemic. Her BMI was 22. Her temperature was normal. Abdominal examination revealed mild supra pubic tenderness. Gynecological examination revealed large irreducible procidentia (Fig. 1).

There was no decubitus ulcer but there was massive oedema and congestion. There was complete eversion of vagina. The prolapse was irreducible. She was admitted. Dressings with magnesium sulfate were started to reduce the edema.

The patient developed retention of urine and fever. She was catheterized. The urine was turbid. She was administered intravenous antibiotics (first generation cephalosporins). Her urine output remained adequate.

However the fever spikes continued and she developed loose stools 4-5 times a day provoked by intake of food and liquids. It was small in amount, not associated with blood mucus. There was no associated vomiting. There was diffuse dull pain in the lower abdomen. Investigations revealed hyponatremia with high blood sugar. There was leukocytosis with neutrophilia. In consultation with physician she was started on insulin and normal saline along with oral rehydration solution and intravenous fluids and switched over to Ciprofloxacin injection. The electrolyte imbalance was corrected.

Even after change of antibiotics, fever spikes persisted and her general condition deteriorated with pulse rate of 120/ min along with tachypnea and dyspnea. The blood pressure was normal at 130/70 mm of Hg. Abdomen appeared distended but there was no guarding or rigidity. Her urine output was adequate. Scan of abdomen revealed significant

isolated pouch of Douglas (POD) collection, mild hydronephrosis and normal bowel. There was no collection in Morrison's pouch or paracolic gutters.

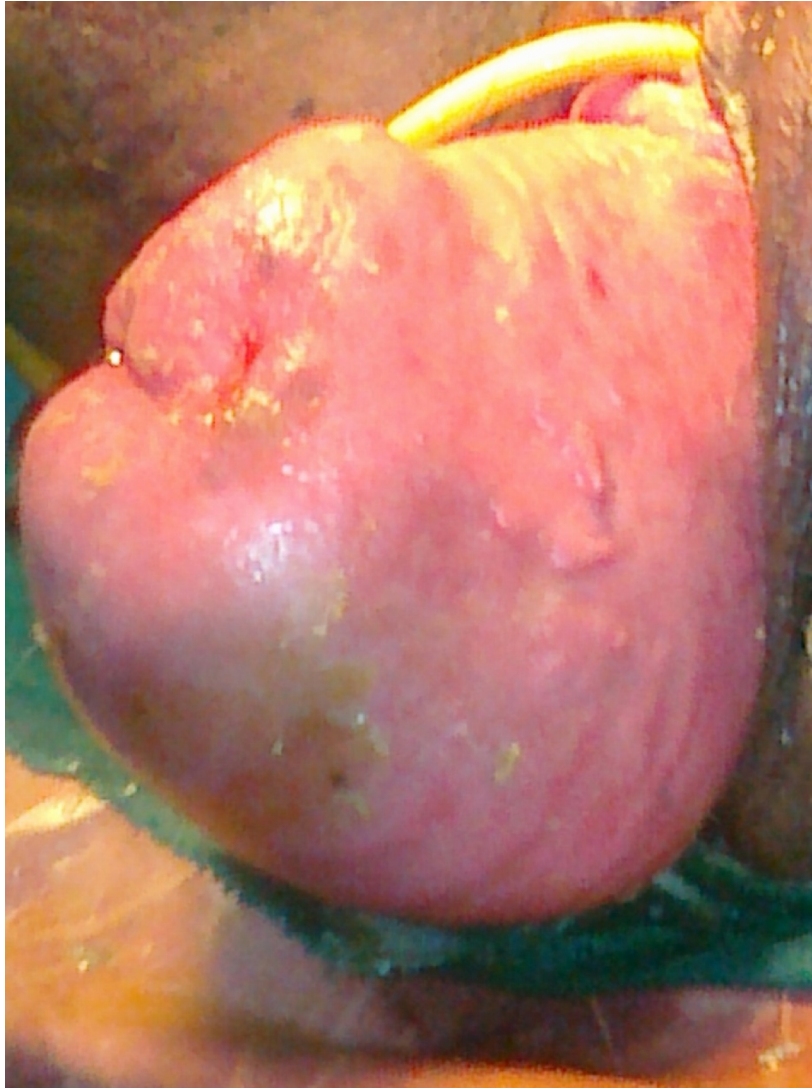

Fig. 1. Incarcerated oedematous congested uterovaginal prolapsed with Foley's catheter in place

In view of persisting fever spikes, irritative diarrhea, features of abdominal compartment syndrome and POD collection, pelvic abscess was suspected. Culdocentesis was performed. It confirmed frank pus in high pressure in the POD. Patient was switched over to injection amikacin (based on the sensitivity pattern of urine culture which grew *Klebsiella* species). The patient was quite ill and CT scan of the abdomen was not easily available to rule out bowel pathology at that hour. In concurrence with anesthetist, emergency colpotomy was carried out under general anesthesia as described previously [6]. The vaginal wall was extremely thickened and oedematous. One and a half litres of foul smelling frank pus was

drained. A corrugated drain was fixed for continued drainage (Fig. 2). Colpotomy was preferred over laparotomy to drain the collection as it was easily accessible, most dependent part and the collection was mostly in the pelvis and not the abdominal cavity.

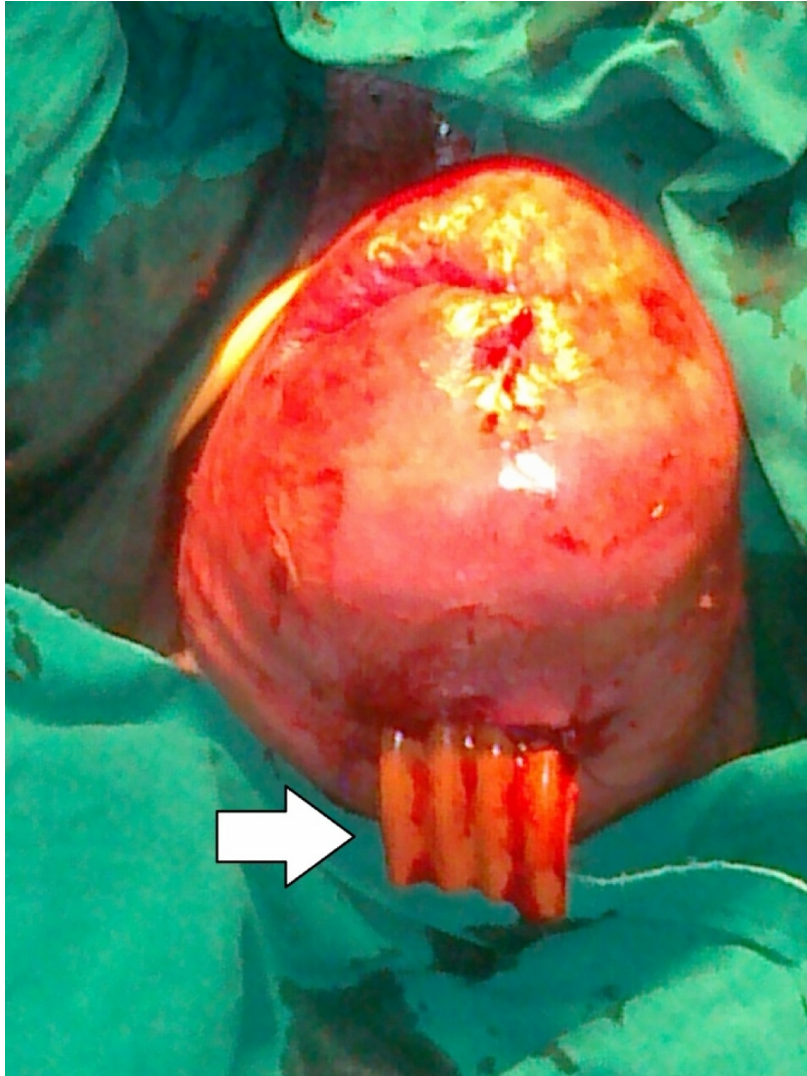


Fig. 2. Post colpotomy view of uterovaginal prolapse with the corrugated drain (arrow) in place

Post operative X-ray Abdomen was normal ruling out possible bowel pathology as the cause for the pelvic abscess.

Patient had a good recovery. Diarrhoea and fever settled. Blood Sugars settled. Post operative recovery was uneventful. Pulse rate and respiration became normal. She felt hungry and was allowed oral after 36 hours. Injection amikacin was continued. She moved bowels normally after 2 days. Drain site became completely dry after 3 days and scan confirmed that the collection had completely subsided. Drain was removed on 5th day. Pus

sent for culture revealed plenty of pus cells but the culture was sterile. Urinary catheter was removed after 1 week and the patient voided without any difficulty. She was discharged after another 2 weeks. She was readmitted after 1 month for definitive surgery. The congestion and edema of the prolapse had reduced considerably. Prolapse was now reducible (Fig. 3).

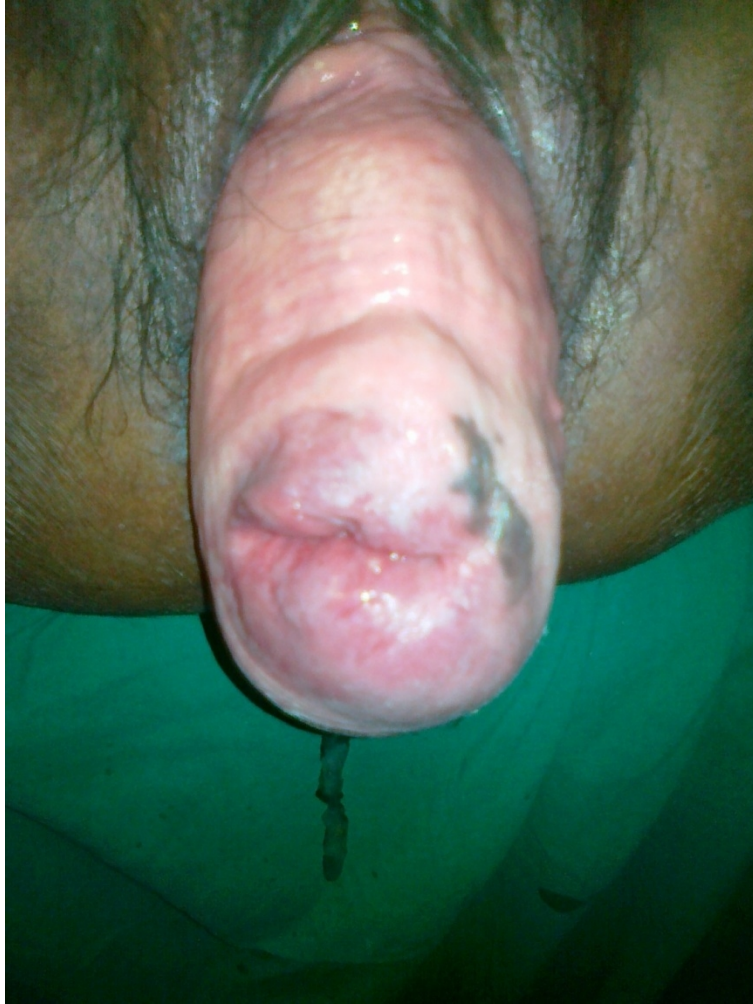

Fig. 3. Incarcerated uterovaginal prolapse 1 month after colpotomy, the prolapse is healthy and reducible

Blood biochemistry was normal. Urine was sterile. Blood sugar level was normal.

Vaginal hysterectomy and extensive pelvic floor repair and vault suspension was carried out as per procedures described previously [7]. Organized inflammatory thickening at the colpotomy site made the dissection a little difficult. There was no longer any POD collection. Both ovaries were normal. She was given intra operative blood transfusion. Post operative recovery was uneventful. Urinary catheter was removed after two days. Patient was discharged after 8 days. On follow up after two weeks the patient was well with good wound healing. On 3 month follow up the vault had healed well and was high in place.

3. DISCUSSION

Pelvic abscess in women is not uncommon. It commonly occurs if sepsis complicates abortion or child birth. Neglected Intrauterine devices have been reported to cause pelvic abscess [8]. Sexually transmitted diseases are an important cause for grade III pelvic inflammatory disease. Recently pelvic abscess has been observed following artificial reproduction techniques [9,10].

Spontaneous pelvic abscess in the perimenopausal and post menopausal age group is rare. Surgical causes like Crohn's Disease, perforated appendix, cancer of the colon, diverticulitis and tuberculosis etc continue to be more common and important causes in this age group [11]. Surgical interventions like fractional curettage, biopsy and hysteroscopy are also important reported risk factors for pelvic abscess in this age group [12,13].

In the absence of surgical problems and above mentioned risk factors, associated gynecologic pathology has to be ruled out. In a review of tubo-ovarian abscess by Hofmann and colleagues [14], genital tract malignancy was found in 4 out of 9 postmenopausal women with abscess. Abscess following rupture of pyometra forming due to cancer cervix or due to endometritis [15,16] and ovarian abscess due to carcinoma [17,18] have also been reported.

Incarcerated uterine prolapse associated with a cul-de-sac abscess has been reported earlier only by Molinelli and Porges [5]. Their patient had an incarcerated prolapse and the abscess was incidentally discovered at the time of definitive surgery carried out because the prolapse could not be reduced.

The spread to the pelvis could be hematogenous from infected focus elsewhere [19]. The spread can also be across the layers of the uterus due to microabscesses forming on the uterine wall. In the present report probably it was hematogenous spread from the urinary tract as well as infection across the mural thickness of the prolapsed, incarcerated and oedematous uterus.

Two stage operations as performed in the present case give a reasonably good recovery. A planned definitive surgery at a later date reduces the operative morbidity and ensures an uneventful post operative recovery.

4. CONCLUSION

Spontaneous pelvic abscess is a rare but life threatening complication of incarcerated prolapse. A two stage surgery in such a situation is associated with good outcome.

CONSENT

All authors declare that 'written informed consent was obtained from the patient (or other approved parties) for publication of this case report and accompanying images.

ETHICAL APPROVAL

Not applicable.

ACKNOWLEDGEMENTS

There were no funding agencies or sponsors for this study and manuscript preparation.

COMPETING INTERESTS

All the authors declare that there are no competing interests.

REFERENCES

1. White AB, Wai CY, Marinis SI, Schaffer JI. Bilateral ureteric obstruction of a partially duplicated collecting system improves after surgical correction of procidentia: a case report. *J Reprod Med.* 2008;53(6):449-52.
2. Naidu A, Nusee Z, Tayib S. Uterine inversion with massive uterovaginal prolapse and multiple bladder stones. *J Obstet Gynaecol Res.* 2011;37(6):633-5.
3. Ghosh SB, Tripathi R, Mala YM, Khurana N. Primary invasive carcinoma of vagina with third degree uterovaginal prolapse: a case report and review of literature. *Arch Gynecol Obstet.* 2009;279(1):91-3.
4. Gupta N, Mittal S, Dalmia S, Misra R. A rare case of primary invasive carcinoma of vagina associated with irreducible third degree uterovaginal prolapse. *Arch Gynecol Obstet.* 2007;276(5):563-4.
5. Molinelli EA, Porges RF. Incarcerated uterine prolapse associated with a cul-de-sac abscess. *Obstet Gynecol.* 1993;82(4 Pt 2):664-6.
6. Darling MR, Golan A, Rubin A. Colpotomy drainage of pelvic abscesses. *Acta Obstet Gynecol Scand.* 1983;62(3):257-9.
7. Maher CM, Feiner B, Baessler K, Glazener CM. Surgical management of pelvic organ prolapse in women: the updated summary version Cochrane review. *Int Urogynecol J.* 2011;22(11):1445-57.
8. Li CH, Chang WC. Spontaneous perforated pyometra with an intrauterine device in menopause: a case report. *Jpn J Infect Dis.* 2008;61(6):477-8.
9. Al-Kuran O, Beitawi S, Al-Mehaisen L. Pelvic abscess complicating an in vitro fertilization pregnancy and review of the literature. *J Assist Reprod Genet.* 2008;25(7):341-3.
10. Sable DB, Yanushpolsky EH, Fox JH. Ruptured pelvic abscess after intrauterine insemination: a case report. *Fertil Steril.* 1993;59(3):679-80.
11. Jackson SL, Soper DE. Pelvic Inflammatory Disease in the Postmenopausal Woman. *Infectious Diseases in Obstetrics and Gynecology.* 1999;7:248-252.
12. Lipscomb GH, Ling FW. Tubo-ovarian abscess in postmenopausal patients. *South Med J.* 1992;85:696-699.
13. McCausland VM, Fields GA, McCausland AM, Townsend DE. Tuboovarian abscesses after operative hysteroscopy. *J Reprod Med.* 1993;38(3):198-200.
14. Hoffman M, Molpus K, Roberts WS, Lyman GH, Cavanagh D. Tuboovarian abscess in postmenopausal women. *J Reprod Med.* 1990;35(5):525-8.
15. Sameer Vyas, Ajay Kumar, Mahesh Prakash, Rakesh Kapoor, Pankaj Kumar, Niranjana Khandelwal. Spontaneous perforation of pyometra in a cervical cancer patient: a case report and literature review. *Cancer Imaging.* 2009;9(1):12-14.
16. Sarada Prasanna Sahoo, Arun Kumar Dora, M. Harika, K. Ramesh Kumar. Spontaneous uterine perforation due to pyometra presenting as acute abdomen. *Indian J Surg.* 2011;73(5):370-371

17. Wagner A, Russell C, Ponterio JM, Pessolano JC. Ruptured tuboovarian abscess and septic shock with *Clostridium perfringens* in a postmenopausal woman: a case report. *J Reprod Med.* 2009;54(10):652-4.
18. Ben-Baruch G, Menashe Y, Leibovitz S, Schiff E, Menczer J. Pelvic malignancy presenting as a pelvic inflammatory process in pre and postmenopausal women. *Eur J Gynaecol Oncol.* 1991;12:347-349.
19. Guerrier G, Morisse L, Perrin D. Pelvic abscess associated with *Haemophilus influenzae* bacteremia. *Int J Gynaecol Obstet.* 2009;107(2):152-3.

© 2014 Dorairajan et al.; This is an Open Access article distributed under the terms of the Creative Commons Attribution License (<http://creativecommons.org/licenses/by/3.0>), which permits unrestricted use, distribution, and reproduction in any medium, provided the original work is properly cited.

Peer-review history:

The peer review history for this paper can be accessed here:
<http://www.sciencedomain.org/review-history.php?iid=215&id=12&aid=2026>