



Role of Magnetic Resonance Imaging in Herpes Zoster Ophthalmicus Ophthalmoplegia

Sandy Zhou Wenting¹ and Srinivasan Sanjay^{1,2*}

¹Department of Ophthalmology and Visual Sciences, Khoo Teck Puat Hospital, 90 Yishun Central, Singapore.

²Yong Loo Lin School of Medicine, National University of Singapore, Singapore.

Authors' contributions

Author SZW wrote the first manuscript and managed the literature search. Author SS provided the case, reviewed and modified the manuscript. All authors read and approved the final manuscript.

Case Study

Received 27th November 2013

Accepted 9th January 2014

Published 12th February 2014

ABSTRACT

Aims: To hypothesize the mechanisms of herpes zoster ophthalmicus (HZO) related ophthalmoplegia by magnetic resonance imaging (MRI).

Case Presentation: A 61-year-old Chinese man diagnosed with right sided HZO and a positive Hutchinson's sign, subsequently developed right eye complete ptosis, mydriasis and limitation of elevation 1 month after the onset of HZO. MRI showed thickening and enhancement of right oculomotor nerve and enhancement of right extraocular muscles. CSF revealed leukocytosis and positive varicella zoster virus (VZV) DNA without any clinical signs of meningitis. The diagnosis HZO-related ophthalmoplegia and asymptomatic VZV meningitis was made based on the clinical and laboratory findings. The external ocular muscle palsies of this patient were due to both oculomotor nerve palsy and orbital myositis demonstrated by MRI.

Conclusion: The pathogenesis of HZO associated ophthalmoplegia is attributed to multiple factors such as neuritis of the cranial nerve and orbital myositis which can be diagnosed with MRI.

Keywords: Ophthalmoplegia; herpes zoster ophthalmicus; magnetic resonance imaging.

*Corresponding author: E-mail: sanjay_s@alexandrahealth.sg;

1. INTRODUCTION

Herpes zoster (HZ) is caused by reactivation of latent varicella zoster virus (VZV) in cranial-nerve or dorsal-root ganglia, with spread of the virus along the sensory nerve to the dermatome. The lifetime risk of HZ is estimated to be 10% to 20% in Caucasian population, which increases in elderly and immunocompromised people [1,2]. Herpes zoster ophthalmicus (HZO) is a term used when HZ affects the ophthalmic division of the fifth cranial nerve. Ocular manifestations occur in approximately 50% of HZ patients, which can involve all ocular structures without the use of antiviral therapy [3]. Neurological complications such as ophthalmoplegia are reported in 5% to 31% of HZO patients [4-6], the third cranial nerve palsy being the commonest and the fourth cranial nerve palsy being the least [7]. The pathogenesis of ophthalmoplegia complicating HZO remains controversial. HZO-related ophthalmoplegia is traditionally interpreted as perineuritis of the third, fourth and sixth cranial nerves in analogy to optic neuritis. However, patients with HZO and ophthalmoplegia previously classified as cranial nerves palsies might have also been diagnosed as having ocular myositis confirmed with CT (Computed Tomography) or MRI [8]. However, such cases as ophthalmoplegia complicating HZO with MRI confirmed neuritis of the cranial nerve and myositis of the extraocular muscle have rarely been reported [9].

2. CASE PRESENTATION

A 61-year-old Chinese man with a past history of chickenpox at childhood developed sharp, lancinating pain over the right side of the scalp. The patient was immunocompetent without significant medical history. Multiple painful vesicular eruptions were noted on the right side of the forehead and eyelid, accompanied with right eye foreign-body sensation and epiphora three days after the onset of pain. The patient's uncorrected Snellen visual acuity was 6/9 in both eyes. Ophthalmic examination showed multiple vesicles over the distribution of the ophthalmic division of the trigeminal nerve on the right side of forehead and eyelid with positive Hutchinson' sign (skin lesion on the tip of the nose), right eye upper lid edema, blepharitis, mild conjunctival injection, dendritic ulcer with full extraocular movements and intact corneal sensation. The patient was diagnosed to have HZO-related blepharoconjunctivitis, epithelial keratitis and dermatitis, and was started on oral acyclovir 800mg 5 times a day for two weeks, 3% acyclovir eye ointment 5 times a day, topical moxifloxacin 4 times a day and 5% acyclovir skin ointment 3 times a day for 3 weeks. One month after the initial presentation, the patient reported that he was unable to open the right eye. Ophthalmologic examination revealed right eye complete ptosis with significant crusting scarring over the involved periorbital and nasal skin lesion Fig. 1.

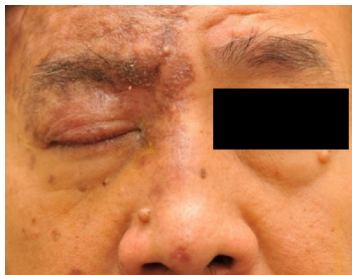

Fig. 1. Right eye lid crusting with scarring over the distribution of the ophthalmic branch of the trigeminal nerve and positive Hutchinson's sign with complete ptosis

The pupils were anisocoric (Right: 5mm, Left: 3mm) and unequally reactive to light (Right: sluggish, Left: brisk). Extraocular motility showed limitation of right eye's elevation Fig. 2.

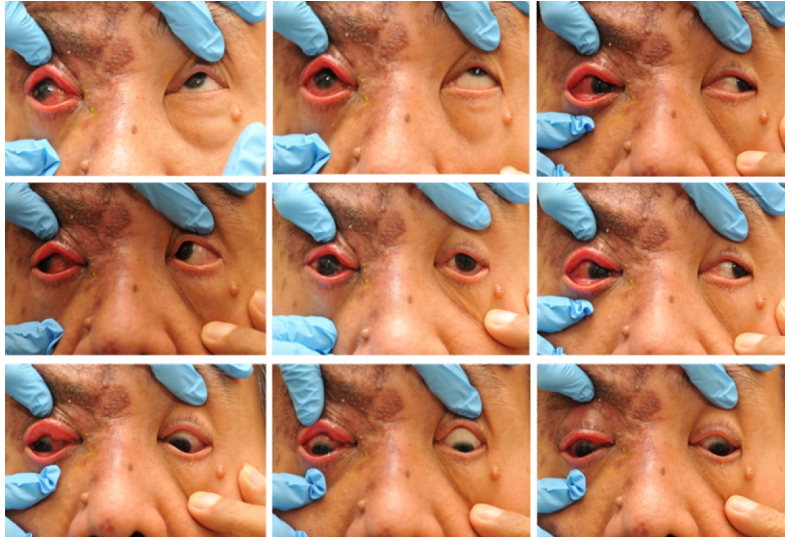


Fig. 2. Nine gaze positions: The range of eye motion of the cardinal position revealed limitation of right eye elevation, adduction and depression

The Hess screen charts demonstrated underaction of the right superior rectus and inferior oblique muscle with overaction of the left superior rectus and inferior oblique muscle Fig. 3.

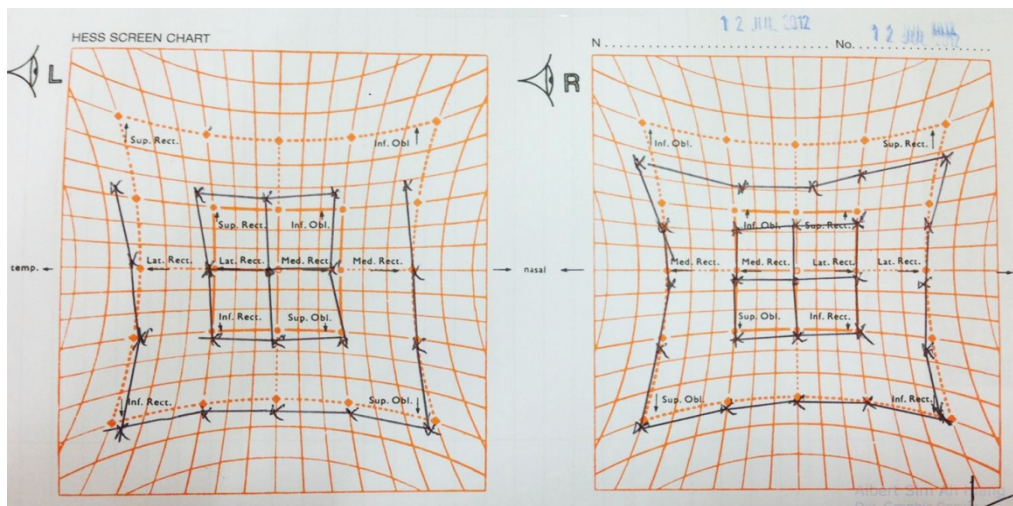


Fig. 3. Hess screen test: Paresis of the right superior rectus and inferior oblique muscle with overaction of the left inferior oblique and superior rectus muscle

Other cranial nerve functions were normal except mild hypoaesthesia over the distribution of the ophthalmic division of the trigeminal nerve on the right side. MRI of the anterior visual pathway showed enhancement and thickening of the cisternal, intracavernous and

intraorbital portions of the right oculomotor nerve and enhancement of right extraocular muscles especially superior rectus and inferior rectus muscle as shown in Fig.4.

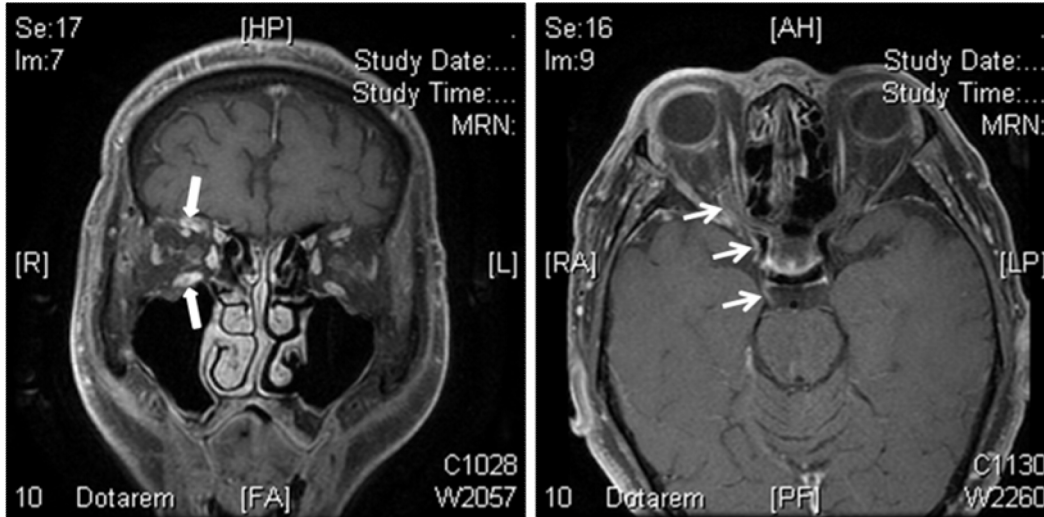


Fig. 4. Post-contrast T1-weighted coronal and axial MRI:

- A) Enhancement and thickening of the right-sided extraocular muscles especially the superior rectus and inferior rectus muscle (wide arrow)**
- B) Enhancement and thickening of the cisternal, intracavernous and intraorbital portions of the right third cranial nerve (narrow arrow)**

Cerebrospinal fluid (CSF) analysis by lumbar puncture yielded a slight leukocytosis (19 white blood cells/mm³) with positive polymerase chain reaction (PCR) result for VZV. The diagnosis HZO-related ophthalmoplegia and asymptomatic VZV meningitis was made based on the clinical and laboratory findings. The external ocular muscle palsies of this patient were due to both oculomotor nerve palsy and orbital myositis demonstrated by MRI. Then acyclovir 750mg was given intravenously for 2 weeks. At a follow-up examination 8 weeks later, complete resolution of ophthalmoplegia with full extraocular movement was found in this patient and oral gabapentin was prescribed for postherpetic neuralgia (PHN).

3. DISCUSSION

Ophthalmoplegia associated with HZO is not uncommon. Extraocular muscle palsies usually appear 2 to 4 weeks after a rash but sometimes occur simultaneously with a rash or more than 4 weeks later. It is a transient, self-limited condition which is rarely seen under the age of 40 [7,10].

The pathogenesis of the extraocular muscle palsies complicating HZO remains controversial. It is traditionally assumed that ophthalmoplegia in HZO occurs due to neuritis of the third, fourth and sixth cranial nerves in analogy to optic neuritis [11]. Carroll et al. hypothesized that the demyelinating process as a possible cause for the reversible optic neuropathy and ocular motor and cerebellar abnormalities in HZO [12]. Marsh et al. Also described a retrograde spread of the virus from the trigeminal ganglion to the fifth nerve nucleus reaching other cranial nerve [7]. However, so far, lesions of the III, IV, or VI cranial nerves in ophthalmic zoster have never been verified pathologically or MR-tomographically

in the previously reported cases and, consequently, the pathogenesis of the external ocular muscles palsies in ophthalmic zoster is still unclear [8,11].

Before the advent of CT and MRI, VZV-induced ocular myositis was an important differential diagnosis to inflammatory involvement of the third, fourth and sixth cranial nerves in HZO-related ophthalmoplegia though without the aid of imaging [7]. Volpe et al. described a case of an orbital myositis with enlargement of the muscle bellies of several ocular muscles shown by CT findings [13]. Kawasaki et al. reported a patient of orbital myositis preceding vesicular eruption with enlargement and enhancement of extraocular muscles consistent with an inflammatory myopathy shown by MRI [14]. Krasnianski et al. described a patient with ophthalmic zoster and external ophthalmoplegia due to ocular myositis demonstrated by MR imaging [8]. Badilla et al. reported a case of orbital myositis involving the oblique muscles with CT showing massive superior and inferior oblique enlargement and moderate enlargement of the remaining extraocular muscles with tendon sparing [15].

Based on the clinical findings of our patient (limitation of right eye elevation, dilated pupil), both superior and inferior divisions of the third cranial nerve were involved, which correlates with the enhancement of the oculomotor nerve along the cisternal, intracavernous and intraorbital portions shown in MRI. However, minimal limitation in depression was detected in this patient, which cannot be completely explained by the third cranial nerve palsy. Thus, other aetiology may exist. Interestingly, in our patient MRI not only showed thickening and enhancement of right oculomotor nerve suggestive of neuritis, but also enhancement of ipsilateral extraocular muscles considering acute orbital myositis. Nevertheless, how orbital myositis contributed to the questionable eye movement in our patient remains unknown. To our knowledge, there's little evidence which supports the hypothesis that HZO-associated ophthalmoplegia may involve multiple mechanisms. Therefore, our case clinically demonstrates different pathogenesis concurrently might contribute to extraocular muscle palsies in HZO.

It is reported that administering acyclovir during the early phase of HZO should be initiated to prevent further ocular complications. However, there are no sufficient data to support treatment of HZO-associated ophthalmoplegia. Since the recovery of the cranial nerve palsy following HZO is found to be usually full even for complete ophthalmoplegia [16], the necessity for any specific treatment for ophthalmoplegia is equivocal [17]. However, systemic antiviral treatment with corticosteroids has been recommended for complete ophthalmoplegia with optic nerve dysfunction which suggests orbital apex syndrome (OAS) to improve visual prognosis. On the other hand, an empirical treatment of 15 to 30 mg of acyclovir per kilogram of body weight for 10 days has been suggested for HZ-associated meningoencephalitis [18]. Subclinical invasion of VZV into the central nervous system (CNS) is relatively common, with approximately one-third of asymptomatic immunocompetent patients having a CSF PCR positive for VZV and 46% of patients demonstrating CSF leukocytosis without any clinical signs of meningitis [19]. Furthermore, abnormal CSF is slightly more in HZO patients with ophthalmoplegia (88%) than those without it [20]. In our case, asymptomatic VZV meningitis was confirmed by CSF results, so we started acyclovir intravenously once the diagnosis was made.

4. CONCLUSION

Patients with HZO and ophthalmoplegia are not uncommon. The pathogenesis of extraocular muscle palsy is attributed by multiple factors such as neuritis of the cranial nerve, orbital myositis which might be detected as MRI or CT is performed.

CONSENT

All authors declare that written informed consent was obtained from the patient for publication of this case report and accompanying images.

ETHICAL APPROVAL

Not applicable.

COMPETING INTERESTS

Authors have declared that no competing interests exist.

REFERENCES

1. Cohen JI. Clinical practice Herpes zoster. *N Engl J Med*. 2013;369(3):255-63.
2. Liesegang TJ. Herpes zoster virus infection. *Curr Opin Ophthalmol*. 2004;15(6):531-6.
3. Liesegang TJ. Herpes zoster ophthalmicus natural history, risk factors, clinical presentation, and morbidity. *Ophthalmology*. 2008;115(2):3-12.
4. Ragozzino MW, Melton LJ 3rd, Kurland LT, Chu CP, Perry HO. Population-based study of herpes zoster and its sequelae. *Medicine (Baltimore)*. 1982;61(5):310-6.
5. Haargaard B, Lund-Andersen H, Milea D. Central nervous system involvement after herpes zoster ophthalmicus. *Acta Ophthalmol*. 2008;86(7):806-9.
6. Sanjay S, Chan EW, Gopal L, Hegde SR, Chang BC. Complete unilateral ophthalmoplegia in herpes zoster ophthalmicus. *J Neuro-ophthalmol*. 2009;29(4):325-37.
7. Marsh RJ, Dulley B, Kelly V. External ocular motor palsies in ophthalmic zoster: a review. *Br J Ophthalmol*. 1977;61(11):677-82.
8. Krasnianski M, Sievert M, Bau V, Zierz S. External ophthalmoplegia due to ocular myositis in a patient with ophthalmic herpes zoster. *Neuromuscul Disord*. 2004;14(7):438-41.
9. Paraskevas GP, Anagnostou E, Vassilopoulou S, Spengos K. Painful ophthalmoplegia with simultaneous orbital myositis, optic and oculomotor nerve inflammation and trigeminal nucleus involvement in a patient with herpes zoster ophthalmicus. *BMRJ Case Rep*; 2012. Pii: bcr2012007063.
10. Marsh RJ, Cooper M. Ophthalmic herpes zoster. *Eye (Lond)*. 1993;7:350-70.
11. Womack LW, Liesegang TJ. Complications of herpes zoster ophthalmicus. *Arch Ophthalmol*. 1983;101(1):42-5.
12. Carroll WM, Mastaglia FL. Optic neuropathy and ophthalmoplegia in herpes zoster ophthalmicus. *Neurology*. 1979;29(5):726-9.
13. Volpe NJ, Shore JW. Orbital myositis associated with herpes zoster. *Arch Ophthalmol*. 1991;109(4):471-2.
14. Kawasaki A, Borruat FX. An unusual presentation of herpes zoster ophthalmicus: orbital myositis preceding vesicular eruption. *Am J Ophthalmol*. 2003;136(3):574-5.
15. Badilla J, Dolman PJ. Orbital myositis involving the oblique muscles associated with herpes zoster ophthalmicus. *Ophthal Plast Reconstr Surg*. 2007;23(5):411-3.
16. Sanjay S, Huang P, Lavanya R. Herpes zoster ophthalmicus. *Curr Treat Options Neurol*. 2011;13(1):79-91.
17. Park KC, Yoon SS, Yoon JE, Rhee HY. A case of herpes zoster ophthalmicus with isolated trochlear nerve involvement. *J Clin Neurol*. 2011;7(1):47-9.

18. Gilden DH, Kleinschmidt-DeMasters BK, LaGuardia JJ, Mahalingam R, Cohrs RJ. Neurologic complications of the reactivation of varicella-zoster virus. *N Engl J Med.* 2000;342(9):635-45.
19. Srinivasan S, Ahn G, Anderson A. Meningoencephalitis-complicating herpes zoster ophthalmicus infection. *J Hosp Med.* 2009;4(6):19-22.
20. Haanpaa M, Dastidar P, Weinberg A, Levin M, Miettinen A, Lapinlampi A, et al. CSF and MRI findings in patients with acute herpes zoster. *Neurology.* 1998;51(5):1405-11.

© 2014 Wenting and Sanjay; This is an Open Access article distributed under the terms of the Creative Commons Attribution License (<http://creativecommons.org/licenses/by/3.0>), which permits unrestricted use, distribution, and reproduction in any medium, provided the original work is properly cited.

Peer-review history:

The peer review history for this paper can be accessed here:
<http://www.sciencedomain.org/review-history.php?iid=430&id=23&aid=3609>